

LETTER TO JMG

8p23 duplication reconsidered: is it a true euchromatic variant with no clinical manifestation?

C-H Tsai, S L Graw, L McGavran

J Med Genet 2002;**39**:769-774

Multiple patients with rearrangements of the short arm of 8p23.1 have been reported, including inverted and tandem duplications of 8p, deletions of 8p23, pericentric inversions (p23q22), and isolated duplications of 8p23. The clinical significance of duplication of 8p23.1 remains controversial. Krasikov *et al.*¹, Williams *et al.*², Barber *et al.*³ and O'Malley and Storto⁴ together have reported 29 patients in 13 kindreds with duplication of 8p23.1, the vast majority (27/29) of whom were phenotypically normal. One case² was reported to be a developmentally delayed 18 month old male and one patient³ underwent cytogenetic analysis because of short stature. In most of these families (9/13), duplication of 8p23.1 was an incidental finding identified during prenatal diagnosis either for advanced maternal age or indicated by a previous child with an unrelated chromosomal abnormality. Two of the remaining cases³ had a history of spontaneous miscarriages. In many cases there has been no long term follow up to examine the possibility of developmental delay or other problems that may arise after the neonatal period. Recently, Engelen *et al.*⁵ reported a 34 year old healthy and developmentally normal man with duplication of 8p23.1-p23.3 who underwent a cytogenetic examination because of oligoasthenozoospermia. Based on his otherwise normal phenotype, they consider this duplication to be a clinically innocuous rearrangement, but could not exclude a relationship between the oligoasthenozoospermia and the duplication. Gibbons *et al.*⁶ reported on a mother and her two daughters with dup 8p23.1. All three had minimal pathology (the mother had bilateral clinodactyly but no other dysmorphic features, and the daughters had smallish heads and mild facial dysmorphism) and normal development. FISH analysis with 8p23.1 YAC HTY3020 showed an apparent duplication.

Others, however, have found that duplication of 8p23.1 can be associated with significant pathology. Kennedy *et al.*⁷ studied a 16 year old female patient with congenital heart defects accompanied by otherwise normal development. Karyotypic analysis showed dup 8p23.1. The patient's father has an isolated right aortic arch and is mosaic for the 8p23.1 duplication. Kondoh *et al.*⁸ reported a patient with dup 8p23.1 and features of Coffin-Lowry syndrome (CLS), including moderate mental retardation along with multiple physical abnormalities. Analysis of the CLS gene, *RSK2*,⁹ showed no mutations. The clinical findings in this patient, including mental retardation, hypotonia, and short stature, are similar to features described in our patients.

CASE REPORTS

Case 1

The male proband was born at term to a 28 year old, G1 P0 mother by vaginal delivery. Birth weight was 2551g. At birth, hypertelorism, thick lips, a protruding tongue, and bilateral inguinal hernia were noted. Subsequently hypotonia and speech and cognitive delay were identified. At 4 years 10 months of age, he was functioning at a three year level. The medical history was significant for frequent upper respiratory

infections. The feeding history was normal. An x ray of his forearm showed radioulnar synostosis with congenital dislocation of the radial head. High resolution karyotype showed a 8p23.1 duplication. The maternal karyotype was normal and the paternal karyotype showed the same duplication 8p23.1. His father was, however, reportedly normal with no history of developmental delay, although he was not formally evaluated by a geneticist.

Case 2

This male proband was ascertained as a newborn with cyanotic congenital heart disease. He was born to a G2 P1 TAB1, 16 year old mother at 40 weeks' gestation by vaginal delivery following an uncomplicated pregnancy. Birth weight, length, and head circumference were at the 75th centile, and Apgar scores were 7 at one minute and 8 at five minutes. Physical examination showed no strikingly abnormal facies, a barrel chest with bilateral rales on auscultation, and a single heart sound with holosystolic murmurs and a prominent S3 gallop. Cardiac catheterisation subsequently confirmed aortic atresia, endocardial fibroelastosis, and congestive heart failure. Mild organomegaly was also noted. Given the grave outcome of such cardiac defects, treatment was withheld and the proband was placed in hospice care and died a few days later. A karyotype showed 8p23.1 duplication. Chromosome analyses were not performed on the parents of this child.

Case 3

All three children in the family, proband 1 (male), proband 2 (female), and proband 3 (male), were evaluated in the Genetics Clinic because of developmental delay. Proband 1 was born to a G2 P2, 37 year old mother at 40 weeks of gestation with a birth weight on the 5th centile. He was noted to have a 1st degree hypospadias at birth. Physical examination performed at 9 years of age showed short stature, midface hypoplasia, bilateral upswEEP, upward slanting palpebral fissures, a long, thin nose, high palate, retrognathia, prominent medial incisors, and short fifth fingers and toes. Medical history was complicated by strabismus and latent nystagmus but otherwise normal vision. He was admitted to the Child Psychiatric Unit of The Children's Hospital, Denver, CO, because of visual and auditory hallucinations, where a diagnosis of pervasive developmental disorder was made. His IQ was 50. His karyotype was normal, 46,XY. Other examination for his developmental delay included thyroid profile, lead level, carnitine, serum amino acid urine organic acids, brain imaging, and fragile X analysis, all of which were normal.

Probands 2 and 3 were born two years later following an uneventful twin pregnancy with birth weights on the 5th centile. Amniocentesis had indicated normal karyotypes. Proband 2 had micronystagmus and optic nerve hypoplasia and a normal brain CT scan. She had mild to moderate developmental delays but good verbal skills and was very sociable. Physical examination at 6 years of age showed height and weight below the 5th centile, midface hypoplasia with a long, straight nose, high arched palate, and a systolic murmur over the left upper

Table 1 Karyotypes and clinical findings of the patients and family members with dup 8p23.1

Family	Case	Karyotype	Dev delay	Cardiac	Short stature	Hypotonia	Other
I	1 proband	46,XY,dup(8)(p23p23)pat	+	–	–	+	Ulnar synostosis, craniostenosis
	2 father of proband	46,XY,dup(8)(p23p23)	–	–	–	–	Phenotypically normal
II	1	46,XY,dup(8)(p23p23)	?	+ Aortic atresia, endocardial fibroelastosis, congestive heart failure	–	?	Mild organomegaly Death in neonatal period Parental chromosomes not analysed
III	1 sib of 2, 3	46,XY	+	–	+	–	Pervasive developmental disorder, unusual facies
	2 sib of 1, twin of 3	46,XX,dup(8)(p23.1p23.1)mat	+	+ Systolic murmur	+	–	Unusual facies; murmur resolved at age 10
	3 sib of 1, twin of 2	46,XY,dup(8)(p23.1p23.1)mat	+	–	+	?	Autistic-like features, aggressive behaviour, unusual facies
	4 mother of 1, 2, 3	46,XX,dup(8)(p23.1p23.1)	?	?	+	?	Multiple miscarriages, graduated high school
IV	1 proband	46,XY,dup(8)(p23.1p23.1)pat, del(15)(q11q13)	+	?	?	+	Features consistent with Prader-Willi syndrome
	2 father of proband	46,XY,dup(8)(p23.1p23.1)	–	+ Atrial fibrillation	?	–	
V	1	46,XY,dup(8)(p23.1p23.1)	?	+ Hypoplastic left heart syndrome	?	?	Death in neonatal period Parental chromosomes normal
VI	1	46,XY,dup(8)(p23.1p23.1)	+	–	?	+	Gastro-oesophageal reflux, unusual facies Parental chromosomes normal
VII	1 proband	46,XY,invdup(8)(p23.1p23.1)mat	+	?	?	?	Seizure disorder, scoliosis, facial dysmorphism
	2 mother of proband	46,XX,invdup(8)(p23.1p23.1)	?	?	?	?	No information available
VIII	1 proband	46,XY,dup(8)(p23.1p23.1)mat	+	–	–	–	Autistic-like features, developmental delay
	2 mother of proband	46,XX,dup(8)(p23.1p23.1)	–	–	–	–	Phenotypically normal

sternal boarder. She was re-evaluated at the age of 10. She can participate in a regular classroom setting, but feels more comfortable in a special education classroom setting. Her facial features remained unchanged. She no longer had a murmur and her vision was within the normal range.

Proband 3 had frequent ear infections, asthma, strabismus, chronic constipation, and sleep disturbance. He was admitted to the Child Psychiatric Unit for aggressive behaviour and psychotic-like symptoms. He had global developmental delay more severe than observed in his twin sister. He had poor speech skills but relatively normal motor skills. An EEG and a brain CT scan were both normal. Physical examination showed a full upper lip with a broad columella, small teeth, broad nasal tip with a slight notch, a slightly asymmetrical chest with a mild parasternal protrusion, short bilateral fifth fingers, and webbing of the second and third toes. External rotation of the feet was observed while he walked, and a large mouth and fair skin were noted. He also showed autistic tendencies, such as hand flapping, gaze aversion, and self-destructive behaviour. When he was re-evaluated at 10 years of age, he had developed minimal speech and still had autistic-like features. Methylation analysis for Angelman syndrome was normal.

Karyotyping of the twins showed duplication of 8p23.1. The family history is significant for the mother with the same duplication 8p23.1 who has reported 13 miscarriages. Her first child died at 2 hours of age with unknown aetiology. Her only three live born children were described as above. She also has nine brothers and four sisters. One brother was reported to have died at less than 1 year of age and one within five days of birth. No information on the causes of death was available. She graduated from high school and has worked as a nursing aid. On brief examination, she had short stature, long big toes,

and an external deviation of the second toes and short fifth toes. She was otherwise healthy. Information about the father was limited.

Case 4

The male proband was first seen at 3 years of age for evaluation of developmental delay and hypotonia. Genetic evaluation and high resolution karyotype showed 46,XY,dup(8)(p23.1p23.1),del(15)(q11q13) and clinical constellations consistent with Prader-Willi syndrome. The maternal karyotype was normal and the paternal karyotype showed 46,XY,dup(p23.1-p23.1). The father had atrial fibrillation but otherwise was reportedly healthy. Physical examination of the proband showed classical features of Prader-Willi syndrome. FISH showed deletion of *GABR3* and *SNRPN* DNA sequences, consistent with the diagnosis of Prader-Willi syndrome.

Case 5

This male proband was ascertained as a newborn with hypoplastic left heart syndrome. A karyotype showed 8p23.1 duplication. Parental karyotypes were normal. The child died when in hospice care on day 2 and no further studies were pursued.

Case 6

This male proband was first seen at 3 months of age because of severe hypotonia. He was born AGA at term to a G3 P2, 28 year old mother. He had an early history of feeding problems, and was diagnosed with moderate gastro-oesophageal reflux with G tube placement with Nissen. An MRI at 3 weeks of age and a muscle biopsy at 1 month of age were normal. Urine amino acids showed slightly increased cystine levels, and a carnitine profile showed slightly increased carnitine esters. Quantitative serum amino acids, thyroid profile, lactate and pyruvate,

Table 2 Summary of clinical findings in patients with dup 8p23.1

Developmental delay or history of developmental delay	6/9 (67%)	I.1, III.2, III.3, IV.1*, VI.1, VII.1, VIII.1
Short stature	3/8 (38%)	III.2, III.3, III.4, IV.1*
Cardiac anomalies	4/10 (40%)	II.1, III.2, IV.2, V.1
Hypotonia	2/7 (29%)	I.1, VI.1, VII.1, IV.1*
Autistic and PDD spectrum	2/9 (22%)	III.3, VIII.1
Other birth defects	7/12 (58%)	I.1, II.1, III.2, III.3, III.4, IV.1*, VI.1, VII.1

*Also has a deletion of chromosome 15 and features of Prader-Willi syndrome.

VLCFA, and acyl carnitine profile were normal. Chromosome analysis showed a duplication of 8p23.1. Physical examination showed tactile defensiveness, widely spaced eyes, downward slanting palpebral fissures, right ptosis, folded auricle and low set, posteriorly rotated ears, broad nasal bridge, high arched palate, short neck, mild 2-3 cutaneous toe syndactyly, retrognathia, and decreased reflexes. He has frequent episodes of pneumonia requiring hospitalisation and recurrent otitis media, along with a history of developmental delay. His two older sibs have normal chromosomes and are reported to be in good health and developmentally appropriate. Parental chromosomes are reported to be normal. Family history was negative for birth defects and multiple miscarriages.

Case 7

This 32 year old male proband born to a 26 year old mother was first ascertained through the orthopaedic clinic at 18 years of age, and was shown to exhibit profound mental retardation (cerebral palsy), seizure disorder, muscle weakness, and severe scoliosis. He was ambulatory with abnormal gait and was non-verbal. Record review indicates that he also had facial dysmorphism, small teeth, and gum hypertrophy, and a diagnosis of CHARGE association was suggested. The patient, however, was never formally evaluated by a clinical geneticist. High resolution karyotype showed 8p23 duplication in both the proband and his mother. No additional history was available on the parents.

Case 8

This 4 year 1 month old boy was first evaluated in the clinic with inherited duplication of chromosome 8p23.1 (mat) and

autistic behaviour. He was the product of a twin pregnancy to a 33 year old, G1 P0-1 LC 0-2 mother via in vitro fertilisation. Pregnancy was complicated by premature labour. The proband was twin B, delivered vaginally with breech presentation, and weighed 1616 g (10%) with Apgar scores of 6 at one minute and 8 at five minutes. He required NICU care for five weeks. Gaze avoidance and tactile defensiveness were noted as early as 3 months of age, as well as a limited tolerance to new foods and different textures. Cytogenetic analysis showed duplication of chromosome 8, band 23.1. FISH for 15q duplication, *FMRI* analysis for fragile X syndrome, and thyroid studies were normal. Parental chromosome analysis showed that the proband's mother, who was healthy and phenotypically normal, also had the same 8p23.1 duplication. A maternal grandfather, maternal uncle, and maternal cousin were reported to have sensory integration disorders, but no chromosome analysis has been undertaken. Physical examination showed an alert boy with major tactile defensiveness. His height was 99 cm (10th-25th centile), weight was 13.6 kg (3rd-10th centile), and head circumference was 49 cm (35-50%). He has normal facial features and normal general paediatric examination. Autistic and rocking behaviour were observed.

METHODS

High resolution cytogenetic studies were performed using phytohaemagglutinin stimulated, methotrexate synchronised lymphocyte G band preparations.¹⁰ Karyotypes were prepared from photomicrographs or digital computer images. The karyotypes for each patient are described in table 1 using ISCN 1995.

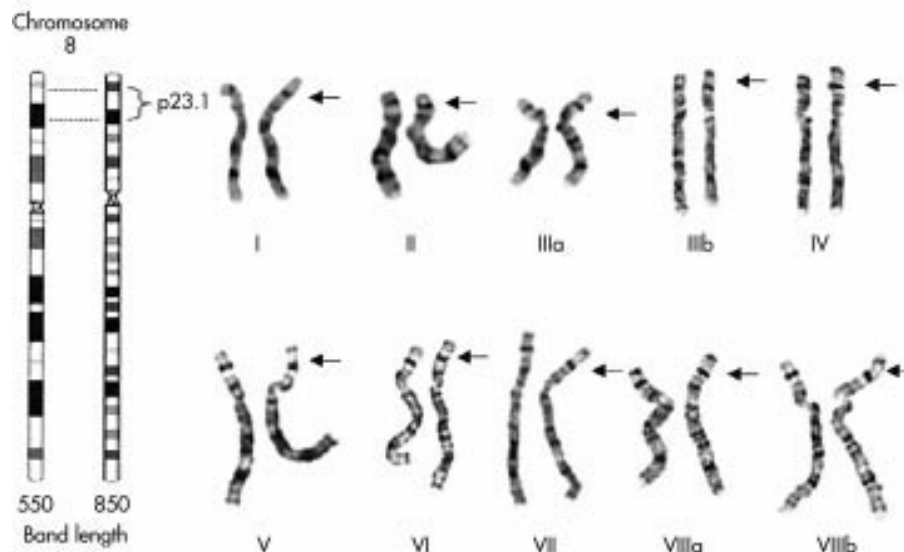


Figure 1 Duplications within band 8p23.1 are shown by G band analysis for each proband and/or family member. The image for case I shows the chromosome 8 homologues with duplication 8p23.1 in the father. Cases IIIa and IIIb are the male and female twin probands. Cases VIIa and VIIb show the karyotypes of the proband and his mother.

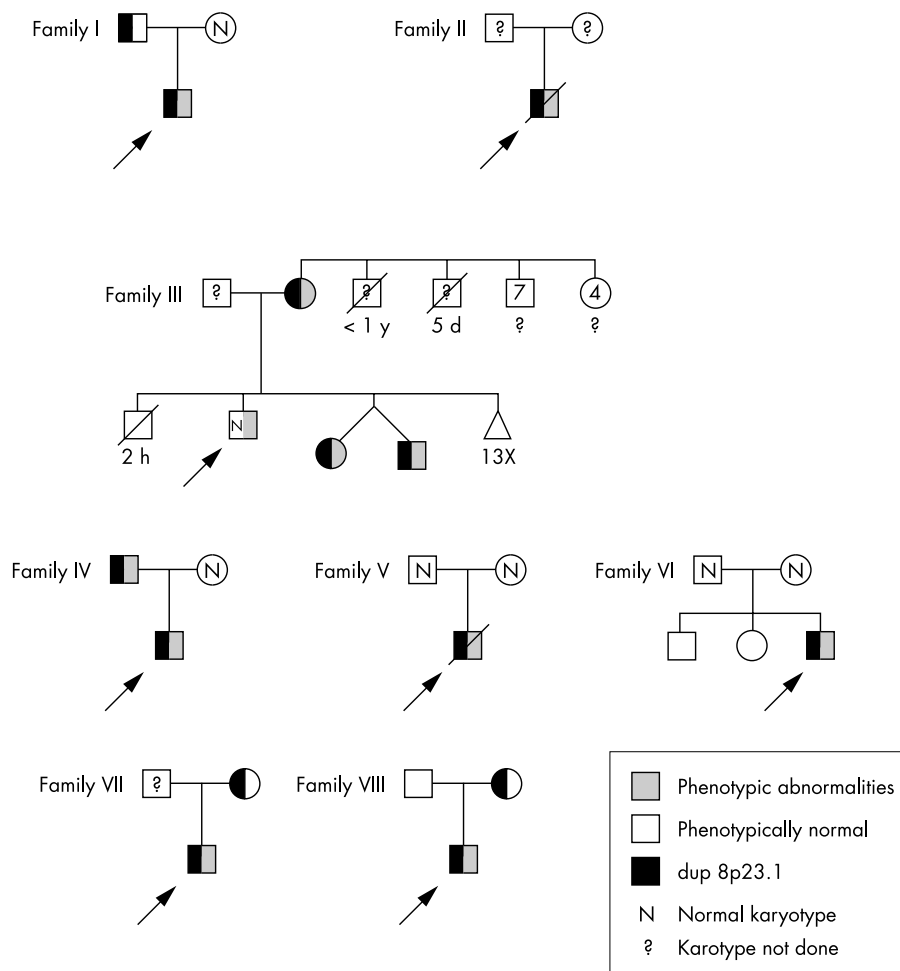


Figure 2 Pedigrees of families.

RESULTS

We have used standard cytogenetic analysis to identify 14 subjects in eight kindreds as carriers of a duplication of 8p23.1. In fig 1, duplications within band 8p23.1 are shown by G band analysis for each proband and/or family member. In each case, band 8p23.1 is significantly larger in one homologue, as indicated by the arrow. A summary of clinical findings and karyotypes in these cases is shown in table 1, and the pedigrees are presented in fig 2. In our eight kindreds, there were five cases of affected parent-child pairs, 2 de novo cases, and one case in which parental chromosomes were not analysed. Of the 14 dup 8p23.1 cases (including both probands and family members carrying the dup 8p23.1), 10 are males and four are females. Because case IV.1 also has a deletion of chromosome 15, and his features are consistent with Prader-Willi syndrome, his information was not included in the percentage. However, to be complete, he is listed in table 2 with an asterisk. The following numbers represent the percentage of patients exhibiting a specific feature where it could be ascertained from either direct physical examination or from the patient's medical records, including the normal subjects (table 2). The most common feature of our cases is developmental delay, which is found in 6/9 (67%) of cases. The second most prominent feature includes some type of cardiac dysfunction in 4/10 (40%) of cases, and serious cardiac malformations in 2/10 (20%) of cases. One of these cases (III.2) was initially described as having a systolic murmur that had resolved upon re-examination at the age of 10. In another case (IV.2), atrial fibrillation was noted in the father of a proband (IV.1). Two cases (II.1 and V.1) were noted to have

significant cardiac abnormalities, which contributed to their deaths in the neonatal period. Short stature is the next most common feature and is found in 3/8 (38%) cases. Hypotonia was found in 2/7 (29%) of cases in which it could be ascertained. Autistic-like features were noted in 2/9 (22%). Both cases represent male probands born to mothers carrying the 8p23.1 duplication. Several other birth defects were noted in individual cases, including ulnar synostosis, craniosynostosis, organomegaly, microcephaly, seizures, scoliosis, and gastro-oesophageal reflux, and multiple miscarriages.

DISCUSSION

The Cytogenetics Laboratory at the University of Colorado Health Sciences Center performed approximately 14 000 constitutional cytogenetic studies (including peripheral blood, prenatal diagnosis, and tissue samples) in the five year period from 1993 to 1998. Fifty-four patients with an abnormality of chromosome 8 were ascertained. Of these, 12 were shown to have a duplication of 8p involving band 23. Members of families III to VII were ascertained during this time period. More recently, the laboratory has identified an additional patient with an inherited duplication of 8p23.1 (family VIII). It is difficult to ascertain the frequency of interstitial dup 8p23.1 in the population because cases are often difficult to detect without high resolution analysis, and the true incidence may therefore be under-reported. We recognise that ascertainment of our patients is biased since every patient came in with a concern. Two cases (II.1 and V.1) were referred for congenital heart defects, three cases (I.1, IV.1, and VII.1) primarily because of developmental delay/mental retardation, and one

each for pervasive developmental disorder (III.1), severe hypotonia (VI.1), and autistic-like features (VIII.1). In addition, analysis of family members of probands has led to the identification of several subjects who also carry the dup 8p but have no recognisable phenotypic abnormalities. In family I, the father of the proband was a carrier of the same 8p23 duplication, yet had a normal phenotype. Family III is especially complex. The oldest sib had normal chromosomes, yet had many of the same phenotypic features (short stature, developmental delay, psychiatric disturbances) as his two sibs and mother with 8p23 duplication, and the possibility of some other syndromic form of mental retardation in this family must be considered. In family IV, 8p23 duplication was found in conjunction with classical features of Prader-Willi syndrome, which was supported by FISH detection of a chromosome 15 deletion. The proband's father also had dup 8p23.1, with minimal phenotypic features. In sum, it is difficult to dissect the relationship between the chromosomal anomaly from other genetic and environmental factors, and the question of why some patients with dup 8p23.1 display pathological features while others are phenotypically normal remains unanswered.

There may be several explanations for the differences in phenotypic expression of patients with dup 8p23.1, even within the same family. In some cases, the observed pathology may be unrelated to the duplication. Some of these phenotypic differences may result from differences in the amount and nature of the duplicated material, and studies are under way to define the breakpoints and associated aneuploid material in these patients. Because of the complex and unstable nature of this chromosomal region, it is also possible that further rearrangements have occurred in the affected family members, leading to additional aneuploid material. Alternatively, other alleles in the genomes of some subjects may be able to compensate more effectively for the 8p23.1 aneuploidy, or there may be some epigenetic mechanism that increases or decreases susceptibility to the pathological features we have noted. Because of these issues, it is important that additional patients be published, ascertained both through routine prenatal diagnosis and through evaluation of children presenting with medical problems. It is especially critical that these children are followed up to detect any association between 8p23 duplication and long term complications.

Previous studies have implicated the 8p23 band as containing a gene or genes critical for normal cardiac development.^{11,12} Recently, Devriendt *et al*¹³ have defined an 8p heart defect critical region (8p-HDCR) and suggested the *GATA4* transcription factor as a candidate gene, and Pehlivan *et al*¹⁴ have shown haploinsufficiency for *GATA4* in several patients with interstitial deletions of 8p23.1 and congenital heart disease. Studies by Giglio *et al*¹⁵ on 12 new patients, including one with Recombinant 8 syndrome, led to the exclusion of *GATA4* as the sole causative factor in the development of congenital heart disease in these patients. The authors postulated that haploinsufficiency for a gene between WI-8327 and D8S1825 contributed to the cardiac pathology found in some of their cases.

Two of our patients (III.3 and VIII.1) were found to have autistic-like features. This finding is especially interesting in light of reports linking 8p to a variety of psychiatric illnesses and behavioural problems. However, whole genome scans for autism susceptibility genes have been undertaken, but have not suggested 8p.¹⁶ Claeys *et al*¹⁷ reported on three new patients and two previously reported patients who had terminal deletions of chromosome 8, four patients with del(8)(p23.1→pter), and one patient with del(8)(p22.1→pter). Three children (one died in infancy) displayed a variety of behavioural problems, primarily aggressiveness and destructive behaviour. Tsai *et al*¹⁸ presented a familial case with dup 8p22.1-23.1 in a mother and child in which the mother had adult onset major depression and obsessive compulsive behaviour. The daughter developed strong

obsessive trait at 10 years of age, but had not been depressed clinically. Other psychiatric traits such as harm avoidance,¹⁹ bipolar disorder,²⁰ schizophrenia,²¹⁻²⁴ Tourette syndrome,²⁵ and panic disorder²⁶ have been linked to chromosome 8p.

The mechanism by which 8p23.1 participates in chromosome instability and rearrangement is beginning to be understood. Repeat sequences within band 8p23.1 might facilitate unequal recombination events, as proposed by Florida *et al*²⁷ as the mechanism leading to formation of inverted duplications involving 8p23.1. Recently, Giglio *et al*²⁸ showed that unequal crossing over between olfactory receptor gene clusters mediates the formation of several 8p23.1 rearrangements, including inv dup(8p), +der(8p) and del(8p), and inv(8p). Sequence analysis of the 8p23.1 breakpoint in San Luis Valley (SLV) Rec8 syndrome²⁹ has shown that the chromosomal rearrangement took place in a genomic region containing multiple repetitive elements immediately telomeric to the olfactory receptor proximal repeat (REPP).²⁸ The dup 8p23.1 cases presented here may also be associated with these olfactory receptor gene clusters, with formation of these small duplications mediated by these repetitive elements. Additional molecular and cytogenetic analyses are under way and should disclose the molecular bases of these rearrangements.

The patients presented here, along with the analyses of the Recombinant 8 syndrome 8p23.1 breakpoint and the region bordered by the olfactory receptor clusters as defined by Giglio *et al*,²⁸ indicate that DNA sequences in 8p23.1 contribute to multiple cases of chromosome instability. In addition, these patients represent confirmation of studies that have postulated the presence of genes critical for normal cardiac development in the region. Current studies to define the exact nature of the duplications in our patients will give us greater insight into the nature of the pathology in these patients, as well as the mechanism of chromosome duplication and the relationship between this region and psychiatric and cardiac disorders.

Importantly, our patients may provide relevant information for genetic counselling concerning the natural history and prognosis for patients with this duplication. We propose that while counselling prenatal cases, some concerns need to be addressed and a detailed examination for such defects as heart anomalies be undertaken before completely reassuring patients that this anomaly is a normal euchromatic variant.

ACKNOWLEDGEMENTS

This is contribution number 1807 from the Eleanor Roosevelt Institute. This work was supported by a grant from the Dorothea Haus Ross Foundation to SLG. We acknowledge with thanks the technologists of the Colorado Genetics Laboratory for their cytogenetic expertise, and Lynne Meltesen, BS, for performing the FISH studies.

Authors' affiliations

C-H Tsai, L McGavran, Department of Pediatrics, Division of Genetics and Metabolism, The Children's Hospital, Denver, and University of Colorado Health Sciences Center, Denver, CO, USA

S L Graw, Eleanor Roosevelt Institute, Denver, CO 80206, USA

L McGavran, Colorado Genetics Laboratory, Department of Pathology, University of Colorado Health Sciences Center, Denver, CO, USA

Correspondence to: Dr S L Graw, Eleanor Roosevelt Institute, 1899 Gaylord Street, Denver, CO 80206-1210, USA; sgraw@eri.uchsc.edu.

REFERENCES

- Krasikov N**, Lamb AN, Vetrano LA, Hansen JL, Menges DE, Lytle CH, Roherty SL, Davenport MB, Pauker S, Dolkart L, Davis G. Benign variant 8p23.1? *Am J Hum Genet* 1992;**53**:A568.
- Williams L**, Larkins S, Roberts E, Davison EV. Two further cases of variation in band 8p23.1. Not always a benign variant? *J Med Genet* 1996;**33**:A3.
- Barber JC**, Joyce CA, Collinson MN, Nicholson JC, Willatt LR, Dyson HM, Bateman MS, Green AJ, Yates JR, Dennis NR. Duplication of 8p23.1: a cytogenetic anomaly with no established significance. *J Med Genet* 1998;**35**:491-6.

- 4 **O'Malley DP**, Storto RD. Confirmation of the chromosome 8p23.1 euchromatic duplication as a variant with no clinical manifestations. *Prenat Diagn* 1999;**19**:183-4.
- 5 **Engelen JJ**, Moog U, Evers JL, Dassen H, Albrechts JC, Hamers AJ. Duplication of chromosome region 8p23.1→p23.3: a benign variant? *Am J Med Genet* 2000;**91**:18-21.
- 6 **Gibbons B**, Tan SY, Barber JCK, Ng CF, Knight LA, Lam S, Ng I. Duplication of 8p with minimal phenotypic effect transmitted from a mother to her two daughters. *J Med Genet* 1999;**36**:419-22.
- 7 **Kennedy SJ**, Teebi AS, Adatia I, Teshima I. Inherited duplication, dup(8)(p23.1p23.1) pat, in a father and daughter with congenital heart defects. *Am J Med Genet* 2001;**104**:79-80.
- 8 **Kondoh T**, Takano J, Sugawara H, Ida T, Harada N, Matsumoto T, Matsumoto N, Niikawa N. Clinical manifestations of Coffin-Lowry syndrome associated with de novo 8p23 duplication. *Am J Hum Genet* 2001;**69**:A646.
- 9 **Trivier E**, De Cesare D, Jacquot S, Pannetier S, Zackai E, Young I, Mandel JL, Sassone-Corsi P, Hanauer A. Mutations in the kinase *Rsk-2* associated with Coffin-Lowry syndrome. *Nature* 1996;**384**:567-70.
- 10 **Verma RS**, Babu A. G-bands by trypsin using Giemsa (GTG). In: *Human chromosomes. Manual of basic techniques*. New York: Pergamon Press, 1989:47-9.
- 11 **Marino B**, Reale A, Giannotti A, Digilio MC, Dallapiccola B. Nonrandom association of atrioventricular canal and del(8p) syndrome. *Am J Med Genet* 1992;**42**:424-7.
- 12 **Digilio MC**, Giannotti A, Marino B, Dallapiccola B. Atrioventricular canal and 8p- syndrome. *Am J Med Genet* 1993;**47**:437-8.
- 13 **Devriendt K**, Matthijs G, Van Dael R, Gewillig M, Eyskens B, Hjalgrim H, Dolmer B, McGraughan J, Brondum-Nielsen K, Marynen P, Fryns JP, Vermeesch JR. Delineation of a critical deletion for congenital heart defects on chromosome 8p23.1. *Am J Hum Genet* 1999;**64**:1119-26.
- 14 **Pehlivan T**, Pobar BR, Brueckner M, Garrett S, Slauch R, Van Rheeden R, Wilson DB, Watson MS, Hing AV. GATA4 haploinsufficiency in patients with interstitial deletion of chromosome region 8p23.1 and congenital heart disease. *Am J Med Genet* 1999;**83**:201-6.
- 15 **Giglio S**, Graw SL, Gimelli G, Pirola B, Varone P, Voullaire L, Lerzo F, Dellavecchia C, Bonaglia MC, Digilio MC, Giannotti A, Marino B, Carrozzo R, Korenberg JR, Danesino C, Sujansky E, Dallapiccola B, Zuffardi O. Deletion of a 5 cM region at chromosome 8p23 is associated with a spectrum of congenital heart defects. *Circulation* 2000;**102**:432-7.
- 16 **Philippe A**, Martinez M, Guilloud-Bataille M, Gillberg C, Rastam M, Sponheim E, Coleman M, Zapella M, Aschauer H, Van Maldergem L, Penet C, Feingold J, Brice A, Leboyer M, and the Paris Autism Research International Sibpair Study. Genome-wide scan for autism susceptibility genes. *Hum Mol Genet* 1999;**8**:805-12.
- 17 **Claeys I**, Holvoet M, Eyskens B, Adriaensens P, Gewillig M, Fryns JP, Devriendt K. A recognisable behavioral phenotype associated with terminal deletions of the short arm of chromosome 8. *Am J Med Genet* 1997;**74**:515-20.
- 18 **Tsai CH**, Conard JV, Van Dyke DL, Bawle EV. Unusual phenotype of inverted duplication of 8p, dup(8)(p23p22), in a mother and a daughter. *5th Joint Conference of MOD and ACMG*, poster 119.
- 19 **Cloninger CR**, Van Eerdewegh P, Goate A, Edenberg HJ, Blangero J, Hesselbrock V, Reich T, Nurnberger J Jr, Schuckit M, Porjesz B, Crowe R, Rick JP, Foroud T, Przybeck TR, Almsay L, Bucholz K, Wu W, Shears S, Carr K, Crose C, Willig C, Zhao J, Tischfield JA, Li TK, Conneally PM, Begleiter H. Anxiety proneness linked to epistatic loci in genome scan of human personality traits. *Am J Med Genet* 1998;**81**:313-17.
- 20 **Ophoff RA**, Service SK, Tampilic M, Eeva M, Sabatti C, Palotie A, Freimer NB. Implications of chromosome 8p inversions for genetic mapping: neuropsychiatric diseases as an example. *Am J Hum Genet* 2000;**69**:A2199.
- 21 **Pulver AE**, Lasseter VK, Kasch L, Wolyniec P, Nestadt G, Blouin JL, Kimberland M, Babb R, Vourlis S, Chen H, Lalioti M, Morris MA, Karayiorgou M, Ott J, Meyers D, Antonarakis SE, Housman D, Kazazian HH. Schizophrenia: a genome scan targets chromosomes 3p and 8p as potential sites of susceptibility genes. *Am J Med Genet (Neuropsychiatric Genetics)* 1995;**60**:252-60.
- 22 **Kendler KS**, MacLean CJ, O'Neill EA, Burke J, Murphy B, Duke F, Shinkwin R, Easter SM, Webb BT, Zhang J, Walsh D, Straub RE. Evidence for a schizophrenia vulnerability locus on chromosome 8p in the Irish study of high-density schizophrenia families. *Am J Psychiatry* 1996;**153**:1534-40.
- 23 **Blouin JL**, Dombroski BA, Nath SK, Lasseter VK, Wolyniec PS, Nestadt G, Thornquist M, Ullrich G, McGrath J, Kasch L, Lamacz M, Thomas MG, Gehrig C, Radhakrishna U, Snyder SE, Balk KG, Neufeld K, Swartz KL, DeMarchi N, Papadimitriou GN, Dikeos DG, Stefanis CN, Chakravarti A, Childs B, Housman DE, Kazazian HH, Antonarakis SE, Pulver AE. Schizophrenia susceptibility loci on chromosomes 13q32 and 8p21. *Nat Genet* 1998;**20**:70-3.
- 24 **Gurling HMD**, Kalsig, Brynjolfsson J, Sigmundsson T, Sherrington R, Mankoo BS, Read T, Murphy P, Blaveri E, McQuillin A, Petursson H, Curtis D. Genomewide genetic linkage analysis confirms the presence of susceptibility loci for schizophrenia, on chromosomes 1q32.2, 5q33.2, and 8p21-22 and provides support for linkage to schizophrenia, on chromosomes 11q23.3-24 and 20q12.1-11.23. *Am J Hum Genet* 2001;**68**:661-73.
- 25 **The Tourette Syndrome Association International Consortium for Genetics**. A complete genome screen in sib pairs affected by Gilles de la Tourette syndrome. *Am J Hum Genet* 1999;**65**:1428-36.
- 26 **Knowles JA**, Fyer AJ, Vieland VJ, Weissman MM, Hodge SE, Heiman GA, Haghghi F, de Jesus GM, Rassnick H, Preud'homme-Rivelli X, Austin T, Cunjak J, Mick S, Fine LD, Woodley KA, Das K, Maier W, Adams PB, Friemer NB, Klein DF, Gilliam TC. Results of a genome-wide genetic screen for panic disorder. *Am J Med Genet (Neuropsychiatric Genetics)* 1998;**81**:138-47.
- 27 **Florida G**, Piantanida M, Minelli A, Dellavecchia C, Bonaglia C, Rossi E, Gimelli G, Croci G, Franchi F, Gilgenkrantz S, Grammatico P, Dalpra I, Wood S, Danesino C, Zuffardi O. The same molecular mechanism at the maternal meiosis I produced mono- and dicentric 8p duplications. *Am J Hum Genet* 1996;**58**:785-96.
- 28 **Giglio S**, Broman KW, Matsumoto N, Calvari V, Gimelli G, Neumann T, Ohashi H, Voullaire L, Larizza D, Giorda R, Weber JL, Ledbetter DH, Zuffardi O. Olfactory receptor-gene clusters, genomic-inversion polymorphisms, and common chromosome rearrangements. *Am J Hum Genet* 2001;**68**:874-83.
- 29 **Graw SL**, Sample T, Bleskan J, Sujansky E, Patterson D. Cloning, sequencing and analysis of Inv8 chromosome breakpoints associated with Recombinant 8 syndrome. *Am J Hum Genet* 2000;**66**:1138-44.



8p23 duplication reconsidered: is it a true euchromatic variant with no clinical manifestation?

C-H Tsai, S L Graw and L McGavran

J Med Genet 2002 39: 769-774
doi: 10.1136/jmg.39.10.769

Updated information and services can be found at:
<http://jmg.bmj.com/content/39/10/769>

These include:

References

This article cites 27 articles, 3 of which you can access for free at:
<http://jmg.bmj.com/content/39/10/769#ref-list-1>

Email alerting service

Receive free email alerts when new articles cite this article. Sign up in the box at the top right corner of the online article.

Topic Collections

Articles on similar topics can be found in the following collections

[Congenital heart disease](#) (82)
[Calcium and bone](#) (307)
[Reproductive medicine](#) (519)
[TB and other respiratory infections](#) (24)

Notes

To request permissions go to:
<http://group.bmj.com/group/rights-licensing/permissions>

To order reprints go to:
<http://journals.bmj.com/cgi/reprintform>

To subscribe to BMJ go to:
<http://group.bmj.com/subscribe/>